

# Postoperative Nasal Retainer for Bilateral Lip and Cleft Palate (BLCP) Pediatric Patients: A Case Report

Aparicio Rodríguez Juan Manuel<sup>a,b</sup>, Marín Melo Jonathan<sup>c</sup>, Ochoa Cáceres Socorro<sup>c</sup>

<sup>a</sup>Genetics, Hospital para el Niño Poblano

<sup>b</sup>Estomatology, Benemérita Universidad Autónoma de Puebla, Mexico

<sup>c</sup>Estomatology, Hospital para el Niño Poblano, Puebla México

---

## Abstract

Treatment of patients with lip and cleft palate requires multidisciplinary management, focused on providing optimal structural, functional, and aesthetic conditions so the patient can develop and achieve a better quality of life. The goal of the estomatologic treatment is to repair altered structures to reach a growth potential and suitable development improving results in surgical times, minimizing adverse effects. One of the treatments for nasal deformity in patients with lip and cleft palate is the use of forming, which are attachments that work the nasal deformity using functional orthopedics; these help avoiding to collapse and relapse the nasal ala, have more permeable airways and eliminate surgical adhesions by secretions or contraction of healing. The objective of this study is to present the case of a female patient of 9-year-old with bilateral lip and cleft palate presenting nasal disorders such as; short nasal projection. It indicated the use of the nasal retainer as postsurgical orthopedic device to improve the structural, functional and esthetic soft tissue deficiencies.

**Keywords:** Lip and cleft palate, inheritance, nasal retainer, functional orthopedics, nasal disorders.

## Introduction

Alterations of cleft lip and palate are considered to be 60 to 70% of congenital malformations, of which a definite cause is not known. The identified causes are: chromosomal alterations 3-5%, , environmental agents 20%, genetic mutations 2-3-%, infections 1% radiation and maternal metabolic alterations 1-3%, drugs and chemical agents 2-3%. The understanding of many of the development and growth disorders that affect the mouth structures is achieved through knowledge of embryology and histology of such structures. The true Etiologic factors present in several alterations of the development and growth of the teeth, jaws and various soft tissues [1]. In some oral diseases, hereditary factors may be decisive or just contribute to a specific condition as will be mentioned later. Most of the cranial malformations are of unknown etiology and as a result,

classification is based mainly on morphological characteristics [2-6]. There are many types of dental anomalies relating to the shape, number and structure, having hereditary origin. The nature of anomalies largely depends on the embryological time in which these clinical features appears, affected embryological layer and also of other external factors. The frequency with which these problems may arise depends on the form of inheritance and other laws of probability.

Some dental anomalies may occur as the only apparent hereditary alteration. Others are presented as part of a much more complex genetic problem. Specifically the congenital absence of one or more teeth can also be a unique problem of hereditary origin. However, the absence of teeth can be part of a syndrome and be related to alterations in the ectoderm as hair, skin and mucous tissues.

In Mexico was established in 1978 the "registration and surveillance epidemiological of the malformations congenital external" (RYVEMCE), generating preventive information programs targeting the population at risk [2, 4-9]. Currently the INFOGEN has been created in the Federal District, as a Centre for the statistics of all kinds of congenital malformations in the Mexican Republic, which the Hospital Para El Nino Poblano is associated.

Cleft li or palate is known to affect approximately one in 700 new born humans in the United States. The reason for this defect lies in a variety of inherited and multifactorial causes in comparison with normal development of the face during embryogenesis. The exact cause for this defect is sometimes confused.

### **Vitamin A and retinoid fetal Syndrome**

It is a characteristic pattern of physical and mental defects at birth resulting from maternal use of retinoid, synthetic derivatives of vitamin A, during pregnancy. The retinoid known as isotretinoína (accutane), a drug used to treat severe cystic acne. The range and severity of associated anomalies may vary before and after birth, malformations of the skull and face, abnormalities of the nervous system, heart and/or additional physical failures. Vitamin a and its derivatives are known as teratogens (any agent that causes a structural abnormality after exposure to the fetus during pregnancy)

Retinoid and vitamin A are well known teratogens in a variety of species. Malformations that are generated depend on the dose used and the time of organogenesis in which are administered. Treatment during the early organogenesis results in cardiovascular and central nervous system anomalies, while a later provision gives rise to genetic defects in the upper and lower limbs, genitourinary tract and palate.

Because of its teratogenic effect has been demonstrated in bioassays with different breeds of animals and epidemiology in humans, retinoid are contraindicated during pregnancy, to such an extent that it must assess the development of pregnancy after treatment with etretinate (Tigason), acitretin (Soriatane), (acid all-trans Retinoic) Tretinoin or isotretinoin (Roaccutane), retinoid use selective in the treatment of acne psoriasis and other skin conditions. These aromatic retinoid are synthetic derivatives of vitamin A with a regulating effect on the epidermal differentiation, immune modulating effect on granulocytes and in addition, a significant inhibitory effect on chorionic gonadotropin. For some of them (isotretinoin), has been determined to have a teratogenic potential up to 45% to prenatal exposure. The risk is high in the first trimester of pregnancy and persists until 1 month after completed treatment. The risk of malformations after the supply of isotretinoin is around 25% in pregnancies that reach the 20th week, comparable in magnitude to the risk of Thalidomide or rubella infection. The supplement of vitamin A in the form of retinol palmitate generates a greater increase in plasma levels of their teratogenic catabolites.

Usually, epidemiological studies of exposure to vitamin A and birth defects are made, but they generally suggest a small increased risk of congenital malformations at doses of vitamin A which far exceed the dose into most of the multivitamins for prenatal use. Recent evidence about daily supplementation above 25 000 UI, who report an increase in the concentration of retinoid in humans, including those with teratogenic effect, have increased the concern over the possible teratogenic potential. Why that is as general line, is accepted that 8000 IU daily supplementation should be considered as the maximum allowable daily dose before or during pregnancy.

### **Cleft lip and palate physiology**

Normally the face tissues develop from either side and fuse in the middle. And it is known to take place within the first 30 to 60 days of pregnancy. This is true for the upper lip and the palate roof of the moth as well. The lip has usually formed by 5-6 weeks of pregnancy and the palate has formed

by 10 weeks. When this union or fusion does not take place normally a separation may form in the upper lip and or the palate. A cleft in the upper lip and palate may often be together. The real reason for this non-fusion is still unknown. Since the lip and the palate develop at different times, they may exist alone as well.

### **Inherited cleft lip and palate**

In some cases this condition may be inherited. Where In their families may exist cleft lips and palates in some members of the family. Cleft lip and palat may be the only abnormality or birth defect in some patients In more than 20% infants the cleft lip and/or palate may be a part of a genetic birth defect syndrome as reported [10-11].

It is possible to detect some symptoms and genetic diseases at birth. For example, Pierre Robin syndrome is a rare condition where the baby is born with a small lower jaw that causes the tongue to fall backwards in their throat. This leads to breathing difficulties. These babies may also have a cleft palat, which usually needs surgery. Or craniofacial malformations as the Opitz G syndrome where hypertelorism [12].

### **Other possible causes of cleft lip and palate.**

Some experts believe there may be nutritional deficiencies or side effects from medications including retinoic acid as mentioned before, that may lead to increased risk of cleft lip and palate [13-17].

Then the above is considered that lip and cleft palate is one alteration that occurs during embryologic development this is characterized by the lack of fusion of facial processes; front nasal medial with the maxillary process, this alteration occurs near the 4th week of intrauterine life; in Mexico about a child in 750 is born with lip and/or cleft palate.

Patients with cleft lip and palate are affected by irregularities in growth and Craniofacial development which causes structural, functional and aesthetic deficiencies in tissues, soft and hard, this coupled with the presence of scars as a result of surgeries of lip and palate as results visible facial stigmata such as: form of flat to concave, nasal asymmetry, malocclusion, phone problems - joint, feeding difficulties and can reach certain degrees of malnutrition, this can lead to a social maladjustment, which makes that the patient was not developed in total fullness [18-22].

The treatment of patients with cleft lip and palate is through a multidisciplinary and comprehensive management, the target is focused on providing optimal structural, functional, and aesthetic conditions so the patient can develop fully and thereby achieve a better quality of life. Therefore one of the main goals in the treatment of cleft lip and palate is structures that are altered to reach a growth potential and appropriate development-help or prepare them for improving outcomes in surgical times and minimize these adverse effects [20]. The labial and alar cartilages which are malformed; on the affected side is flattened and tends to be larger but, at the same time, it is weaker; the shape and position of the same, is altered because instead of a rounded arch that follow the perimeter of the nostril, extends the cartilage as a bridge that crosses the rift.

The columella deviates from the middle line. In patients with an incomplete cleft, the nasal floor is present and with lower on the left side location; those with complete cleft it is absent. The base of the nasal ala usually lateralized and positioned lower in comparison with the healthy side. The alveolus can be deviated wholly or partly, depending on the commitment. The septum is deviated and lateralized to the normal side, in some cases more than others, setting the position of the columella. In all cases the orbicular muscle of the lips is set near the base of the columella, along the philtrum on the medial side and, in the same lip, side cracked. At the time of contract, it tends to distract most opening at the level of the fissure, which demonstrates that the orbicular muscle of the lips is not laterally fixed to the base of the nasal ala [19].

The features of the nose in a cleft lip are:

1. Short collumela.
2. Collumela base diverted towards the normal side.
3. Dome wing with less projection and lateral displacement.
4. Lack of nasal floor.
5. Too open Arch of the nostril.
6. Affected side shifting alar cartilage.
7. Overlap decreased or absent among the cartilages wing and side.
8. Base wing displaced.
9. Abnormal relationship between the layers of skin, cartilage and mucous membrane of the nasal ala.

The cracks where the lip defect has been dealt, but not corrected nasal deformity following situations are, in greater or lesser degree:

1. Cartilage descended wing.
2. Smaller projection and alar cartilage lateralization.
3. Malformation on the wing edge.
4. Asymmetric bases of the nostrils.
5. Severe deviation of the septum, which includes all its segments.
6. Deviation of the nasal pyramid.

According to the classification of Kernahan and Stark the cleft lip and palate primary might be complete and incomplete. When it's complete cleft features that have are little projection of the nasal tip, depressed nasal Dome, columella cut and diverted, the nasal wing is depressed on the side of the fissure, in these cases, attachments can be used as:

1. Presurgical nasal forming:

Before the cheiloplasty nasal forming help manipulate the depression of the nasal ala, improve the nasal tip projection and also help to stretch slightly the columella in early stages.

2. After rhinoplasty nasal forming:

In cases of sequel of lip and palate cleft that is later than primary Rhinoplasty nasal forming help prevent nasal collapse, prevent the relapse of the nasal ala, help to have more permeable Airways and there are no surgical adhesions of nasal secretions and by contraction of the healing [18].

The nasal forming are attachments that act directly on the nasal deformity through the concept of functional orthopaedics with the theory of Roux, founded and supported by the intimate relationship between the shape, structure and function [21-23].

Currently there are prefabricated forming, usually are made of medical silicone, which already have standard sizes and placement according to the chosen measurement is easy. The disadvantages of these forming lie in the high cost that is inaccessible in our country.

The nasal forming manufactured can be produced with different types of biocompatible materials such as:

- Silicone
- Suction tubes
- Nasogastric tubes
- Catheter made of acrylic
- Screw expansion forming made with paper clips.

**Case description:**

A 9-year-old female patient with bilateral LPH, with alar cartilages descended, walking nasal tip projection, asymmetric bases of nostrils and nasal pyramid deviation Figures 1 A and B.

Place retainer for nasal tip projection made for this treatment by the Hospital orthodontic services for the Hospital para el niño Poblano, wired the 0.36 with loops for activation, together with acrylic and supported by elastic as retention Figures 2 A, B, C and D.

The treatment plan was to indicate the use of the nasal retainer with a minimum of 8 hours a day, activation, and measuring every 15 days, and making a monthly measurement.

Measurements were performed taking as points, the base of the nose in relation to the nasal tip, columella, and the height of the nostrils, respectively Figure 3A.

Measurements were performed monthly for 6 months that it triggered the nasal retainer and thrown outcomes are mentioned in Table I.

A nasal conformer of retention is subsequently placed for 6 months which is not already activated to keep the soft tissues in the position that was achieved.

**Discussion and Conclusions***Genetic inheritance of cleft lip and palate*

In genetic inheritance of the condition either parent can pass on a gene or gene that cause clefts. Researchers have identified a number of genes that may be responsible. It is found that children of a parent with a cleft have a 4 to 6 percent chance of being born with clefts. If a child is born with clefts

but neither parent has a cleft, the risk of clefts in a biological sibling is 2 to 8 percent [1-9].

The risk of clefts in biological siblings and future children increases to 15 to 20% if parents as well as the first two children have clefts [13-17]. Children who have no family history of clefts are at 0.14% risk of being born with a cleft lip and/or palate.

#### *Environmental causes of cleft lip and palate*

Environmental causes include poor early pregnancy health and exposure to various toxins during pregnancy. Exposure to alcohol and tobacco are linked to risk of babies born with cleft lip and/or palate.

Mothers who are taking medications for epileps may also be at a higher risk of giving birth to babies with a cleft lip and/or palate, including drugs like:

- Phenytoin,
- Phenobarbital,
- Sodium valproate,
- Benzodiazepines etc.

Those taking corticosteroids, methotrexate (for psoriasis, arthritis or cancers) or isotretinoin (for acne) are also at risk.

#### **Other risks for cleft lip and palate; vitamin A**

As mentioned before, children who come to the specialist with craniofacial malformations represent a major challenge for this. Although these malformations most of the times does not pose a life-threatening, mark the child and his family's life. Many of them will need multiple and complex surgeries to try to get your facial appearance to be as normal as possible. Craniofacial malformations, among its frequency in clinical practice cracks syndromes orofacial (cleft lip and palate) and syndromes of first and second Gill arches as syndromes of Franceschetti-Zwahlen-Klein, Treacher-Collins and hemifacial microsomia.

Although many birth defects have a genetic cause, a considerable group has a multifactorial etiology. It is considered that around 8-10% of congenital malformations are the result of teratogenic agents. These substances include vitamin A as mentioned widely and its derivatives. Cis-Retinoic acid (Accutane) is a synthetic retinoid that began to be used in the United States in 1982 for the treatment of severe cystic acne. Thanks to its



effects on epithelial cell differentiation and low relative toxicity, the results were good from the clinical point of view. Its side effects in adults are minimal, but it cannot be consumed during pregnancy. In 1985 Webster documented congenital defects children.

When the exposure occurred during the first month of gestation, three and a half days were sufficient to cause malformations. The principal defects were cardiovascular, and Craniofacial anomalies such as cleft palate, depression of the midface, anomalies in the maxillary processes and pinna, aortic arches hypoplasics and defects in septation in atria and ventricles. Ester etretinate (Tigason) is a synthetic derivative of vitamin A which began to be used in December 1986 for the treatment of psoriasis. Unlike the Accutane, which has a half-life of 16-24 hours and is metabolized quickly, etretinate is stored in the tissues, and its metabolites have been found up to three years after the initial intake.

Due to its long half-life and persistence of its potential to produce birth defects, it is recommended to be careful with women planning to get pregnant who have been in treatment with etretinate for at least the two years following their employment.

Deficiency of B vitamins and folic acid in maternal diet is another commonly associated cause of cleft lip and palate in the newborn. Parents who are older than usual at the time of birth of their baby are at higher risk of having children with cleft lip and or palate.

A viral infection during pregnancy may also be associated with cleft lip and palate. Mothers who are obese have a higher chance of their child being born with a cleft.

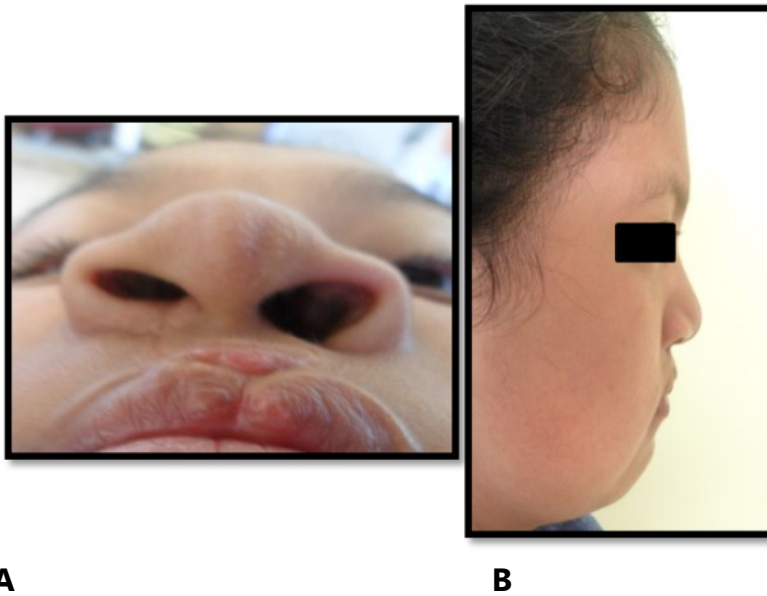
Therefore no matter the cause of this facial defect, the use of nasal Shaper with a minimum use of 8 hours a day, as a postoperative brace in patients with lip and cleft palate allows the projection of the nasal tip, elongation of the columella [18-23]. improving the structural, functional and esthetic soft tissue deficiencies Figures 4 A and B.

### **Acknowledgements**

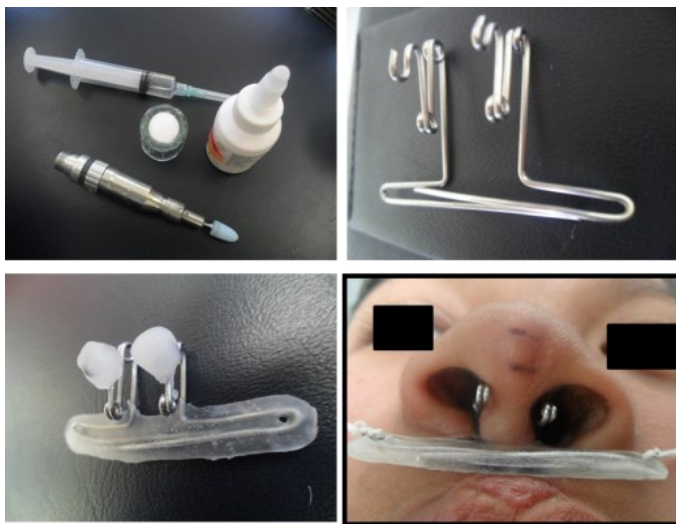In particular the authors would like to thank Dr. Victor Avalos Rodriguez (smile Huasteca BC) who are pioneers in the development of the retainer that was used in this study.

## References

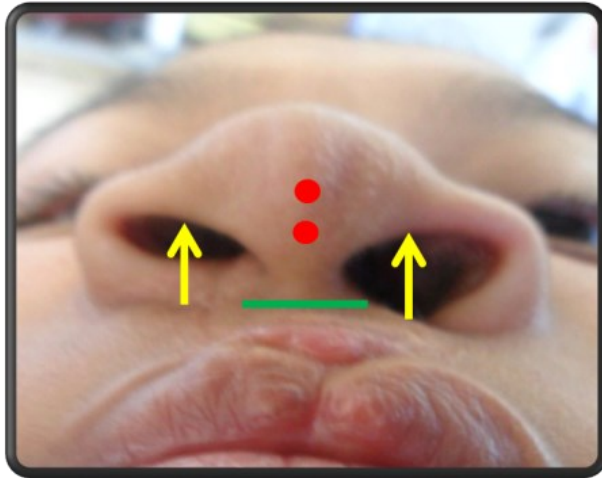
1. Witkop C (1975). Clinicas Odontológicas de Norteamérica. Genética. Interamericana México 35-36.
2. Pinto-Cisternas J (1979). La genética humana en Odontología ¿Algo superfluo o algo fundamental?. ADM; ( 36 ) 5: 561-565.
3. Molina J, Galindo S, Padilla B (1984). Malformaciones Genéticas. PO; (5) 5: 32.
4. Alfaro N, Prado C, López M (1994). Malformaciones congénitas en 75,788 nacimientos consecutivos en cuatro hospitales de Guadalajara, México. Perinatol Reprod Hum: 91-100.
5. Gorlin R.: Thoma Patología Oral. Salvat (1985). 123-125 135-143 151-154 170-174.
6. Shafer W, Levy B (1987). Tratado de Patología bucal. Interamericana México D:F: 3-11.
7. Johnston M.C (1980). Some abnormal paterns of development in the craneo-facial region. The National Foundation of birth defects; (15) 8: 23-42.
8. Goodfrey P (1980). Frecuencia de malformaciones congénitas en seres humanos. Clin Pediatr Nort; (5): 123-133
9. Molina J, Galindo S, Padilla B (1998): Malformaciones Genéticas. La boca y la medicina; 35-41.
10. Aparicio-Rodríguez JM, Hurtado-Hernández MdL, Barrientos-Pérez M (2013). ring chromosomes aberrations at a pediatric mexican hospital. two cases with mosaicism of chromosome 13, 46XY / 46, XY, r (13) and chromosome 18, 46, XY / 46, XY, r (18). Journal of Asian Scientific Research, 3, 174-187.
11. Aparicio-Rodríguez J. M., Hurtado-Hernández M. D. L., Barrientos-Pérez M., Zamudio-Meneses R., Palma-Guzmán M., Chavez-Ozeki H.and Chatelain-Mercado S (2013). Clinical features in a pediatric population due to chromosome deletions at a third level pediatric mexican hospital in 19 years period of time: five case reports. International Journal of Genetics and Molecular Biology, 5, 1-7.
12. Juan Manuel Aparicio-Rodríguez, Ma. De Lourdes Hurtado-Hernandez, Isabel Marroquín-García, Guadalupe Araceli Rojas-Rivera, Patricia Sánchez-Meza, Salvador Rodríguez-Peralta, Rigoberto Zamudio-Meneses, Walter san Martin-Brieke, Eduardo Urzaiz-Rodriguez and Enrique Huitzil-Muñoz (2011). Five opitz G/B.B.B syndrome cases report with two chromosomal abnormalities; X chromosome duplication (47, XXY) and translocation 46XX T (3q;4q). International Journal of Genetics and Molecular Biology, 3, 87-94.
13. [http://www.in.gov/isdh/files/cleft\\_lip\\_palate](http://www.in.gov/isdh/files/cleft_lip_palate)
14. <http://www.gillettechildrens.org/fileupload/cleft%20lip%20and%20palate>
15. <http://www.cdph.ca.gov/programs/CBDMP/Documents/MO-CBDMP-Cleft-Lip-Cleft-Palate-Fact>
16. [http://practicalplasticsurgery.org/docs/Practical\\_2](http://practicalplasticsurgery.org/docs/Practical_2)
17. <http://www.healthpoint.co.nz/default,18293>
18. Méndez R. López J (2005). Conformadores nasales en la rinoplastia primaria del paciente fisurado. Cir. Pediatr; 18: 200-203.
19. Loreto M. Merino G (2011). Rinoseptoplastia en pacientes fisurados. Rev. Otorrinolaringol. Cir. Cabeza y Cuello; 71 (2): 171-178.
20. Ford A (2004). Tratamiento actual de las fisuras labio palatinas. Rev. Med. Clin. Condes; 15(1): 3-11.
21. Muñoz A. Castro L (2006). Ortopedia tridimensional y manejo preoperatorio de tejidos blandos en labio y paladar hendidos. Cir. Plast; 16(1): 6-12.
22. Bercowski D. Stockstill J (2009). Moldeado naso alveolar en el paciente con labio y paladar fisurado unilateral. Rev. Odont. De los Andes; 4 (1): 37-42
23. Castillo T. Yudovich M (2008). Ortopedia funcional y conformadores nasales. Hosp. Gea González.



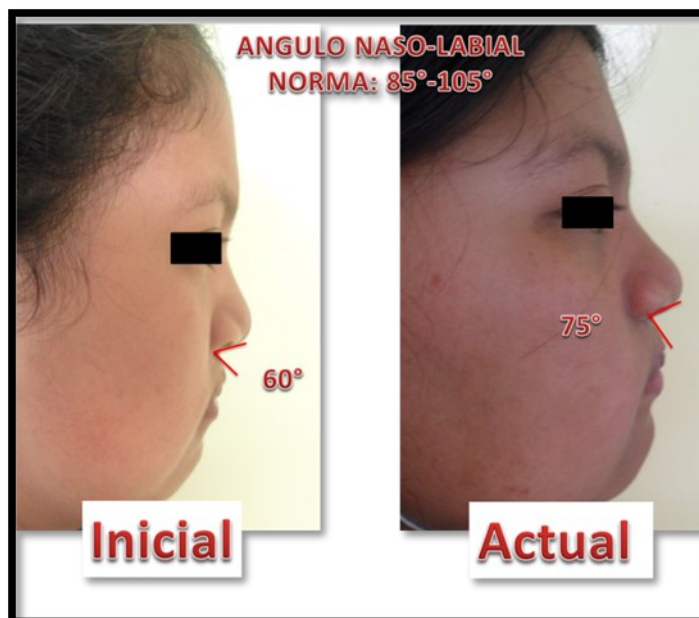**A** **B**  
**Figures 1 A and B** A 9-year-old female patient with bilateral cleft lip and palate, with Alar cartilages descended, walking nasal tip projection, asymmetric bases of nostrils and nasal pyramid deviation



**A, B, D, C.**  
**Figures 2 A, B, C and D** Place retainer for nasal tip projection made for this treatment by the Hospital orthodontic services for the Hospital para el Nino Poblano, wired the 0.36 with loops for activation, together with acrylic and supported by elastic as retention



**Figures 3 A** Measurements were performed taking as points, the base of the nose in relation to the nasal tip, columella, and the height of the nostrils, respectively



**A** **B**

**Figures 4 A and B** The use of nasal Shaper with a minimum use of 8 hours a day, as a postoperative brace in patients with LPH allows the projection of the nasal tip, elongation of the columella improving the structural, functional and esthetic soft tissue deficiencies

**Table I** Measurements were performed monthly for 6 months that it triggered the nasal retainer and thrown outcomes are mentioned in

Date	Nasal tip (mm)	Columella (mm)	Right nostril (mm)	Left nostril (mm)
Sep	13	8	8	9
Oct	13	8	8	9
Nov	13	9	8	9
Dec	14	9	9	10
Jan	15	10	10	10
Feb	15	10	10	10