# The Treatment of Fusiarium Keratitis, A Case Report Of A 32 Years Old Man

**Ardeida Xhamuca**
Department of Ophthalmology, Mother Teresa Hospital, Tirana, Albania

## Abstract

**OBJECTIVE** To describe a case of post traumatic fusiarium keratitis successfully treated with systemic and topical voriconazole.
**CASE SUMMARY** A 32-year-old man was admitted to the hospital with an incisive wound of his left eye and the cornea totally sectioned after trauma with a cutter used in gardening. Visual acuity was 1/10. From laboratory findings, fusiarium was found as the causative agent. An empirical treatment was followed by systemic and topical voriconazole, and the eye did not have to be enucleated. Three months after the trauma, the cornea was transparent and the visual acuity was 7/10.
**DISCUSSION** Fusiarium keratitis must be suspected if a history of ocular injury with contaminated objects exists. Among the antifungals available to treat the fungal keratitis, voriconazole has shown advantages such as the lowest minimum inhibitory concentration and the availability of an oral formulation.
**CONCLUSION** Voriconazole shows promise as an effective alternative to conventional antifungals in the treatment of fusiarium keratitis. It is available both as oral and intravenous preparations, which is a great advantage in these lengthy infections.
**KEYWORDS**: Fusiarium, keratitis, voriconazole

## Introduction

Keratitis is an inflammation of the layers of the cornea. It is most commonly associated with
bacterial or viral microorganisms that invade into the corneal stroma, resulting in inflammation and ultimately, destruction of these structures. Of the organisms that cause keratitis, fungi remain
one of the most elusive and challenging organisms to diagnose and treat. It has also been shown that infection with fungal keratitis (FK) can be more virulent and damaging compared to that of a bacterial origin.
Fungal keratitis in previous retrospective analyses was shown to be more likely to perforate the cornea than bacterial keratitis (OR = 5.86, 95 % CI, 2.06–16.69) and lead to irreversible changes[1,2].
Ocular trauma is a major predisposing factor for fungal keratitis. Microorganism invasion occurs secondary to alterations of the corneal surface, resulting in potential spaces for organisms to track deeper into underlying layers. This invasion leads to a mostly innate and adaptive immune-mediated inflammation, resulting in subsequent tissue necrosis of the surrounding area. As fungi penetrate into the stromal layers of the cornea, there appears to be a reactive innate and adaptive immune response that occurs which consequently leads to further tissue damage, scarring, and therefore, opacification of the cornea. The exact mechanisms of this process, including the specific inflammatory mediators, however, have not yet been fully elucidated[3–4].

If microorganisms penetrate deeper into the corneal stroma, through Descemet's membrane, and into the anterior chamber or sclera, eradication of the organism becomes tremendously difficult. This invasion followed by the subsequent tissue damage that follows is particularly devastating as it can disrupt the visual axis. Early diagnosis and treatment of fungal keratitis is therefore imperative to prevent visual threatening complications[3].

Fusarium species are common organisms that are present in soil, water and plants. Most infections are often preceded by trauma. Other risk factors include the use of antibiotics and corticosteroids, preexisting eye diseases, foreign bodies' surgery and the use of contact lenses. Among Fusarium species, F.solani, F. oxysporum and F. moniliforme are the most frequently implicated in human infections[5].

**Case Report**

A 32-year-old man presented to our hospital with an incisive wound of his left eye and the cornea totally sectioned after trauma with a cutter used in gardening. He complained severe visual loss, photophobia, redness and pain in left eye. Visual acuity was 1/10. Slit lamp examinations revealed conjuctival congestion and a corneal full thick laceration see fig.1.

**Fig. 1**

An empirical treatment was followed by systemic and topical voriconazole suspecting a fusarium infection. In the same time we took a microbial test for eye scrab, and send to the laboratory findings. The answer of the laboratory confirmed the presence of fusiarium. After the confirmation of the diagnosis we decided to add therapy with oral voriconazole, (800 mg per day on the first day, followed by 400 mg per day on successive days) and topical voriconazole eye drops voriconazole 1% (drops every 2 h), diclofenac 01% drops every 8 hours eye drops and moxifloxacin 0.5%,to prevent bacterial sovraposition.

After 14 days the condicion of the patients was not good. The patient showed eye redness, pain, 1/10 of visual acuity, endothelial dusting and aqueous flare and cells see fig.2.

**Fig.2**

As we can se from fig. 2, the eye was red and the fusiarium penetrated in tha anterior chamber. The eye was near to perforate, and the situation was going to bad. Visaual acurity was hand movemant, and edema of the conjuctiva was more expresed.
In this situation we change the tratamet. Oral voriconazole was changed to intravenous formulation, 8 mg/Kg twice per day and intracameral voriconazole was done 2 times a week.

Three months later the situation was improved, cornea was clear and the visual acurity was 3/10 see fig. 3.

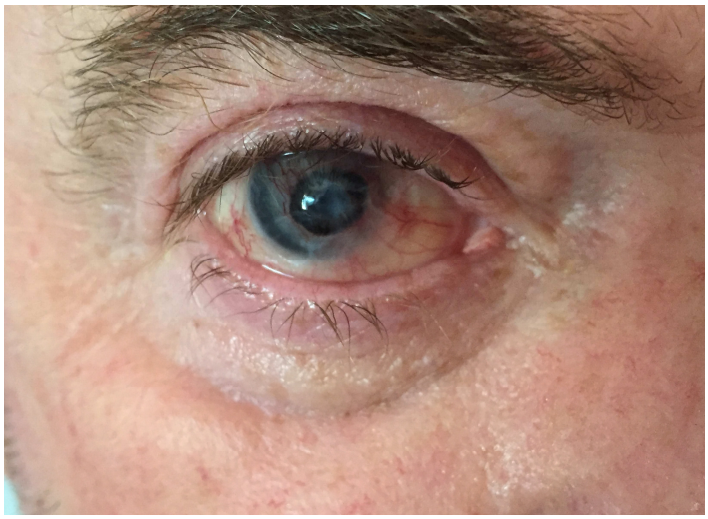

**Fig.3**

We continue the treatment with topically voriconazole and oral voriconazore for other 6 months, and the situation was improved with corneal trasparence and the visual acuity was 6/10.

**Discussion**

Fungal keratitisis an important cause of ocular morbidity and blindness. The diagnose of these infections is very difficult and currently the therapy for fungal diseases is not as forceful and effective as antibacterials. Antifungal drugs have little corneal penetration and low efficiency[6].

Fusarium solani species complex can cause severe types of fungal keratitis because of its high level irulance and its resistence to antifungal medications[7]. It can destroy an eye completly whithin a ew weeks because the infection is usually severe and perforation deep extension.

The most commonly used topical medication for Fusarium keratitis are azole derivates and natamycin. Prajna t al[16] found no difference in three month best spectacle corrected visual acuity or scar size between natamycin and voriconazole treated patients in Fusarium keratitis.

Voriconazole a derivative of fluconazole is a new triazole antifungal agent[8] like other triazoles inhibits cytochrome P450 demethylase, which is essential for the synthesis of ergosterol. It is hypotheized that this adversly affects the permeability of the fungal cell membrane[9]. Voriconazole has excellent oral bioavailability and a broad spectrum of activity. Voriconazole has been shown to be highly effective against filamentous organismand is more potentin invasive aspergillosis than amphotericin B[10,11]. According to a report by Jang et al.[12] voriconazole is also effective against candida chorioretinitis. Our case report indicates that 1% voriconazole is an effective treatmantr for fusarium and unknoun fungal keratitis.

In conclusion voriconazole is a new promising therapy for fungal keratitis.Voriconazole may be considered as a new method to treat fungal keratitis refrectory to standard antifungal therapy.

**Bibliography:**

1. Wong TY, Ng TP, Fong KS, Tan DT. Risk factors and clinical outcomes between fungal and bacterial keratitis: a comparative study. CLAO J. 1997;23:275–281. [PubMed]

2. Sharma N, Chacko J, Velpandian T, et al. Comparative Evaluation of Topical versus Intrastromal Voriconazole as an Adjunct to Natamycin in Recalcitrant Fungal Keratitis. Ophthalmology. 2012 [PubMed] Important trial that compared topical and intrastromal voriconazole in adjunct to natamycin. Showed no significant difference between topical and intrastromal voriconazole in best corrected visual acuity.

3. Sharma S. Diagnosis of fungal keratitis: current options. Expert Opin Med Diagn. 2012;6:449–455. [PubMed]

4. Tarabishy AB, Aldabagh B, Sun Y, et al. MyD88 regulation of Fusarium keratitis is dependent onTLR4 and IL1R1 but not TLR2. J Immunol. 2008;181:593–600. [PMC free article] [PubMed]

5. Dignani MC, Anaissie E. Human fusariosis. Clin Microbiol Infect. 2004;10:67–75. [PubMed]

6,I. Dóczi, T. Gyetvai, L. Kredics, and E. Nagy, “Involvement of Fusarium spp. in fungal keratitis,” Clinical Microbiology and Infection, vol. 10, no. 9, pp. 773–776, 2004. View at

Publisher · View at Google Scholar · View at Scopus

7 E. Speeleveld, B. Gordts, H. W. Van Landuyt, C. De Vroey, and C. Raes-Wuytack, “Susceptibility of clinical isolates of Fusarium to antifungal drugs,” Mycoses, vol. 39, no. 1-2, pp. 37–40, 1996. View at Publisher · View at Google Scholar · View at Scopus 16 V. N. Prajna, P. S. Lalitha, J. Mascarenhas et al., “Natamycin and voriconazole in Fusarium and Aspergillus keratitis: subgroup analysis of a randomised controlled trial,” British Journal of Ophthalmology, vol. 96, no. 11, pp. 1440–1441, 2012. View at Publisher · View at
Google Scholar · View at Scopus
8. Kim KH, Kim MJ, Tehah HW. Management of fungal infection with topical and intracameral
voriconazole. J Korean Ophthalmol Soc. 2008;49:1054–1060.
9 . Lee SB, Park CJ, Kim JY. A Case of Intravitreal Voriconazole for the Treatment of Drugresistant Penicillium Endophthalmitis. J Korean Ophthalmol Soc. 2007;48:1583–1587.
10. Herbrecht R, Denning DW, Patterson TF, et al. Voriconazole versus amphotericin B for primary therapy of invasive aspergillosis. N Engl J Med. 2002;347:408–415. [PubMed]
11. Miller GR, Rebell G, Magoon RC, et al. Intravitreal antimycotic therapy and cure of mycotic endophthalmitis caused by Paecilomyces lilacinus contaminated pseudophakos. Ophthalmic Surg. 1978;9:54–63.[PubMed]
12. Jang GJ, Kim KS, Shin WS, Lee WK. Treatment of Candida Chorioretinitis with Voriconazole.Korean J Ophthalmol. 2005;19:73–76. [PubMed]