Effect of Progesterone upon the Mammary Glands of Albino Rat (Wistar strain): Histological Aspect

Suvarna Rawal,
Dept. Of Zoology, B.N.N. College, Bhiwandi, Dist. Thane, Maharastra(India) 421305

Abstract

Mammary gland is a compound alveolar gland that develops from the lower layer of the epidermis. progesterone is important in normal mammalian physiology. In Natural level progesterone causes the glandular elements of the mammary glands to grow and develop into secretory epithelium. Progesterone as a contraceptive shows direct impact on mammary gland cytoarchitechtural pattern of cell.

KEYWORDS: Progesterone, mammary gland, epithelium, epidermis.

INTRODUCTION:

During the last two decades, there has been a significant progress in the studies of hormonal contraceptives (Natural and Synthetic), such as Progesterone and their effects on the specific target organs. Graham et al. (1997) studied the physiological action of progesterone in target tissues such as mammary gland. As far as progesterone is concerned it is of paramount importance in normal mammalian physiology. Progesterone also causes the glandular elements of the mammary glands to grow and develop into secretory epithelium with the ultimate effect of acting in concern with other hormones particularly PRL, to facilitate milk production (Turner 1976). Topper et al. (1980) suggested that the principal role of progesterone in promoting lobulo-alveolar development in the adult mammary gland. Frantz (1981) did not find progesterone to be necessary for ductal development. Huggins et al. (1962) described for the first time the effect of progesterone on the mammary gland and found that it inhibited the development of carcinogen induced mammary tumour.

Drug Chemistry

Progesterone is a major steroid secreted by the corpus luteum. In 1934, Butenandt, isolated this progestationally active substance (Butenandt and Westphal, 1934). Butenandt announced the complete synthesis of this hormone for which he and his co-workers were awarded the 1935 Nobel prize in chemistry. Progesterone exists as colourless crystals or yellow-white odourless, tasteless powder. It is prepared commercially from diosgenin or stigmasterol, which are obtained from plant sources.

Progesterone $(C_{21}H_{30}O_2)$

Pregn -4 -ene - 3 ,20 - dione.

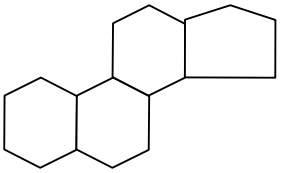

Molecular weight = 314.5

Solubility

In alcohol - 1 in 8

In water - 1 in 10,000)

Toxicology

There is limited evidence that progesterone is carcinogenic in some laboratory species (Kordon et al; 1993 and Misdorp et al; 1992), but there are no epidemiological studies in the human (WHO,1979). The present study is designed to evaluate the possible direct influences of progesterone on mammary gland of albino rat.

MATERIALS AND METHODS

Young, healthy, sexually mature female albino rats of Wistar strain (120-150 gms body weight) with normal reproductive history were procurred from Haffkine Biofarmaceuticals. The animals were kept under uncontrolled room ambient temperature and photoperiod . Food pellets marketed by Lipton India Limited and water provided **ad libitum**. The rats were acclimatized for a month to the laboratory conditions prior to the commencement of any experiment . Animals were divided into two sets control and for drug treatment, for each set of an experiment a population of female rats belonging closely to a certain weight group were selected , the reason for which all the groups of rats at the commencement of the treatment did not weigh the same .

The animals were divided into control and experimental groups. The treatment lasted for 24 weeks duration i.e 24 injection of i.m.injectable progesterone . The drug were of 100% purity which is available in the market with same trade name.

On the completion of the treatment period, the animals were weighed and sacrificed under light ether anaesthesia. The cervix was quickly excised cleared off the adhering fat blotted and weighed after which processed for the various light microscopic study studies .

CONTROL MAMMARY GLAND :

Fig.1(X-40)

Fig. 2(X-120)

Fig.1&2 : Micrograph of control Mammary gland.
Note excretory duct (Exd), adipocytes (Ad),
and intralobular connective tissue.

Mammary gland is a compound alveolar gland that develops from the lower layer of the epidermis . It consists of a number of lobes separated by broad

bands of dense connective tissue . The lobes are divided into lobules by connective tissue septa, from which strands extends into secreting units. The intralobular connective tissue is fine areolar. The alveoli of each lobules open into small intralobular ducts , which unite to form interlobular ducts and these in turn lead to the main excretory ducts (figs.1) .

Stroma : Mammary glands contains a rich network of connective tissue, stroma and varying amounts of adipocytes. Two types of connective tissues are present , 1) interlobular connective tissue composed of variously dense fibrous connectve tissue containing ducts , lobules and clusters of fat cells. 2) Intralobular connective tissue, in which are embedded the ductules and alveoli of each lobules . It has an abundant ground substance and a few reticular fibres but there are no fat cells within lobules (figs. 2) .

Adipose tissue covers the surface of the mammary glands and is also present between lobes of glandular tissue (figs. 1&2).

PROGESTERONE TREATED MAMMARY GLAND:

Fig. 3 (X-40)

Fig.3: Progesterone treated(24 weeks) mammary glands shows Inhibitory tubuloalveolar(Tb) an atrophied duct (Dt).

Progesterone administration to the rat completely inhibits the growth and tubuloalveolar development of the mammary gland. After treatment with progesterone, the mammary gland reveals of a few atrophic ducts, with inactive atrophic epithelial cells and no lobuloalveolar structure (fig.3).In addition, no additional effects on the mammary gland histology are observed. Progesterone does not appear to be promoting lobuloalveolar development. Progestin also stimulates mammary stromal cell synthesis.

DISCUSSION :

The major developmental role of progesterone on the normal breast has been postulated to be the formation of lobular alveolar structures during pregnancy (Topper & Freeman 1980). This is supported by the observation that mammary glands in mice develop ductal structure upon exposure to estrogen and progesterone (Lydon et al. 1995). The influence of progesterone is likely to be proliferative in this process. Progesterone also exert a differentiating effect on the breast through its role in lactation (Dinny Graham, 1997).

But in the present experimental investigation, progesterone of the mammary gland results in atrophy of the epithelial cells & ducts.

However, progesterone either decreases or has no effect on the proliferation of normal breast epithetium in nude mice (McManus et al. (1984) and Laidlaw et al. (1995)). Gompel et al. (1986) reported that the progesterone decreased cell proliferation. Our histological observation with progestogenic agents supports the above results.

Mammary epithelial structures often are growing into a lipid-rich environment of the fat pad. Fatty acids, particularly unsaturated fatty acids, stimulate mammary epithelial cell growth and can substantially enhance the in vitro effects of other growth factors such as IGF-I and EGF. Mammary stromal cells also are involved in dissolving the connective tissue collagen so the epithelial structures can continue to grow. Several proteases involved in tissue remodeling and growth of parenchymal tissue are derived from stromal tissue. Extracellular matrix components, which are important for mammary tissue growth and function, are produced by both epithelial cells and stromal cells. **Mammary Gland Development During the Postpubertal Period (Google net source) 2016.** Present study shows structural changes in mammary gland histology after progesterone treatment. The results are alaraming with reference to level of atrophy.

REFERENCES

1. Brodsky R.A., Hasegawa, S. Fibach, E. Dunbar, C.E., Young N.S. and Rodgers, G.P. (1994). Acquired sideroblastic anaemia following progesterone therapy. **Br. J. Haematol. (1994), 87(4): 859 – 862.**
2. Butenandt and Westphal (1934). Zur Isolierung and charakterisierung des corpus luteum Hormones. Berl. Btsch. Chem. Ges.(1934); 67: 1440.
3. Dinny Graham and Christeine Clark (1997). Physiological action of progesterone in target tissues. **Endocrine. Reviews. (1997), Vol. 18, No. 4: 502 - 518.**
4. Kordon, E.C. Malinolo, A.A., Pasqualini, C.D., Charreu. E.H., Pazas, P. and Lanari, C. (1993). Progesterone induction of mammary carcinomas in BALB/ C female mice. Correlation between progestin dependence and morphology. **Breast Cancer Res. Treat (Nethelands); 28(1): 29 -39.**
5. Mc Donough (1985). Progesterone therapy: Benefits versus risk. **Fertil. Steril. (1985); 44: 13-16.**
6. Topper et al. (1980**)**
7. Text book of endocrinology Turner 1976).
8. Mammary Gland Development During the Postpubertal Period **(Google net source) Jan.2016**